
بسم الله الرحمن الرحيم





کولیت ایسکمیک و ترومبوز وریدپورت

دکتر ناصر ابراهیمی دریانی
فوق تخصص گوارش، تهران



GI Vasculitis

دکتر همایون واحدی
فوق تخصص گوارش، تهران

ISCHEMIC COLITIS

Prof.N E.DARYANI

1405/03/28

IAGH

Intestinal ischemia is caused by a reduction in blood flow to a level that is insufficient for the delivery of oxygen and nutrients required for cellular metabolism .

Three main mechanisms are responsible for intestinal ischemia.

- Nonocclusive colonic ischemia –
- Embolic and thrombotic arterial occlusion –
- Mesenteric vein thrombosis

Spectrum of Ischemic Disease

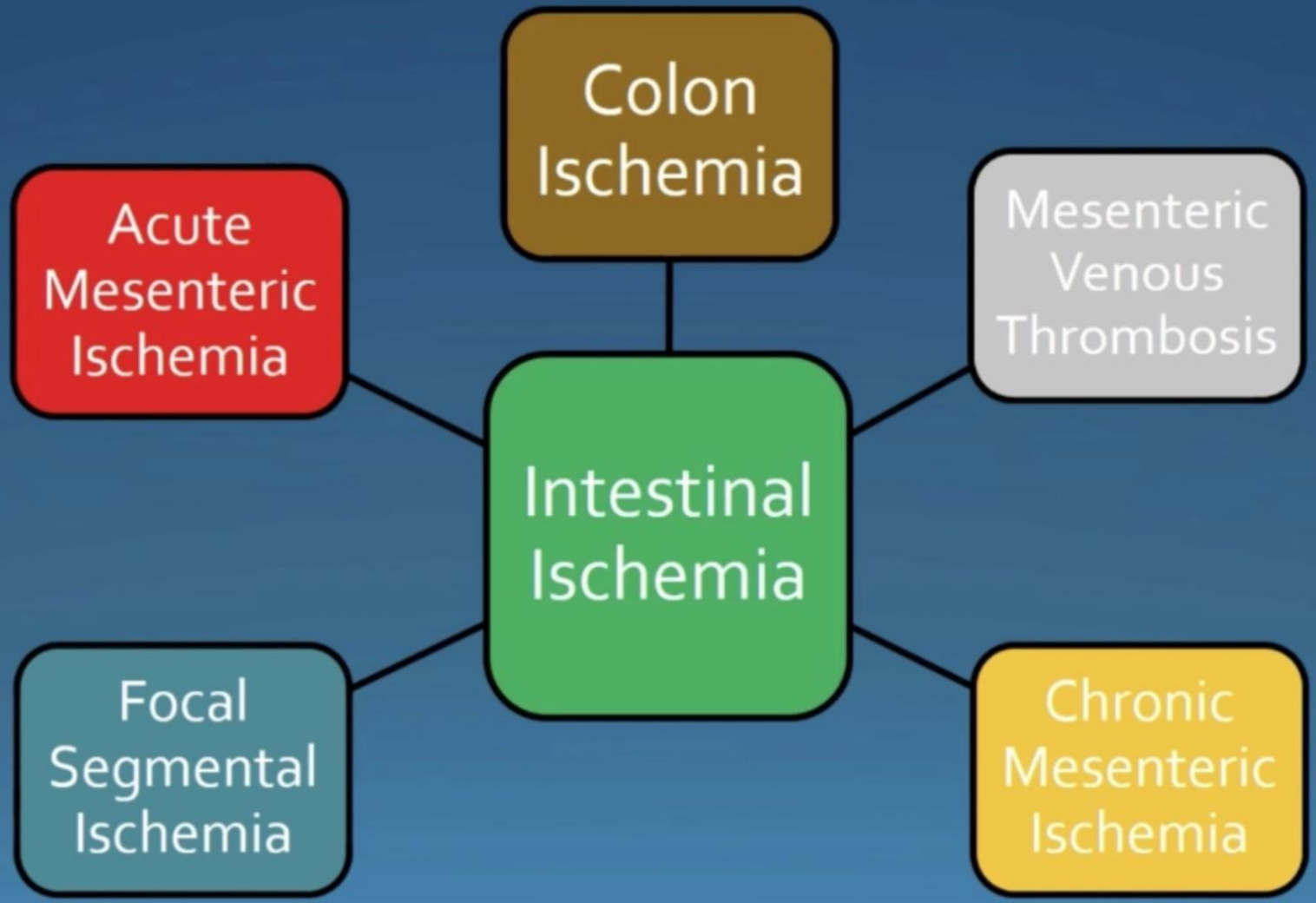

Frequency of Ischemic Bowel Disease

TYPE	FREQUENCY (%)
Colon ischemia*	75
Acute mesenteric ischemia*	25
Focal segmental ischemia*	<5
Chronic mesenteric ischemia	<5

*Includes mesenteric venous thrombosis. Mesenteric venous thrombosis can manifest as colon ischemia, acute mesenteric ischemia, or focal segmental ischemia.

- **Colonic ischemia is the most frequent form of intestinal ischemia, most often affecting older adults .**
- **Colonic ischemia may be more prevalent in females.**
- **Colonic ischemia should be suspected in patients with lower abdominal pain and bloody diarrhea or hematochezia; however, these symptoms are nonspecific**

Approximately 15 percent of patients with colonic ischemia develop necrotic bowel, the consequences of which can be life-threatening, making rapid diagnosis and treatment imperative.



- **Colonic ischemia is usually the result of a sudden, but usually transient, reduction in blood flow, the effects of which are particularly prominent at the "watershed" regions of the colon, where collateral blood flow is limited**

Most cases of colonic ischemia are usually transient and resolve without sequelae .

However, some patients will have a more prolonged course or develop long-term complications, such as stricture or chronic ischemic colitis

Vascular Supply of the Colon

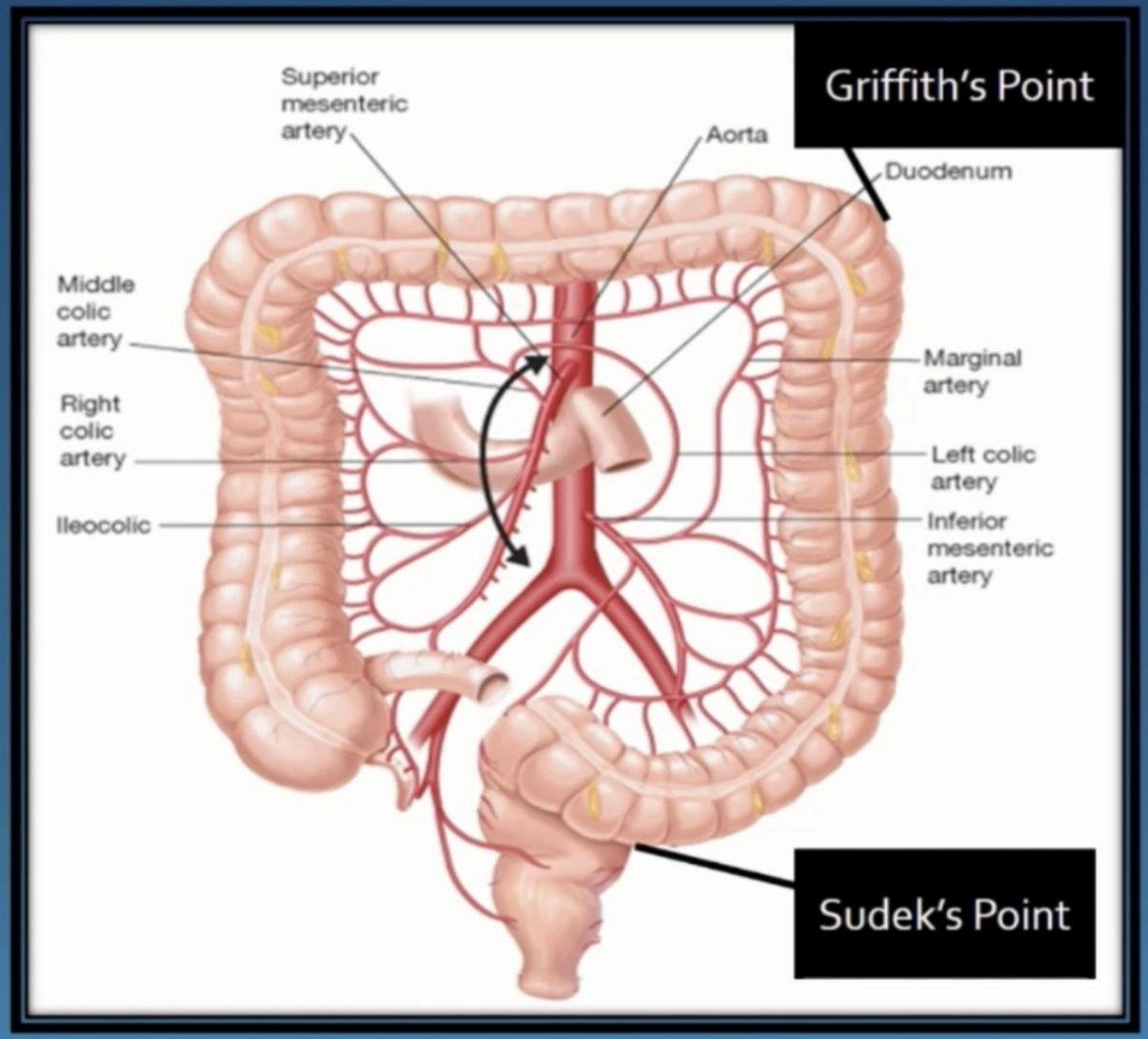

https://thoracickey.com/esophagectomy-transhiatal-and-reconstruction/



Colon Ischemia

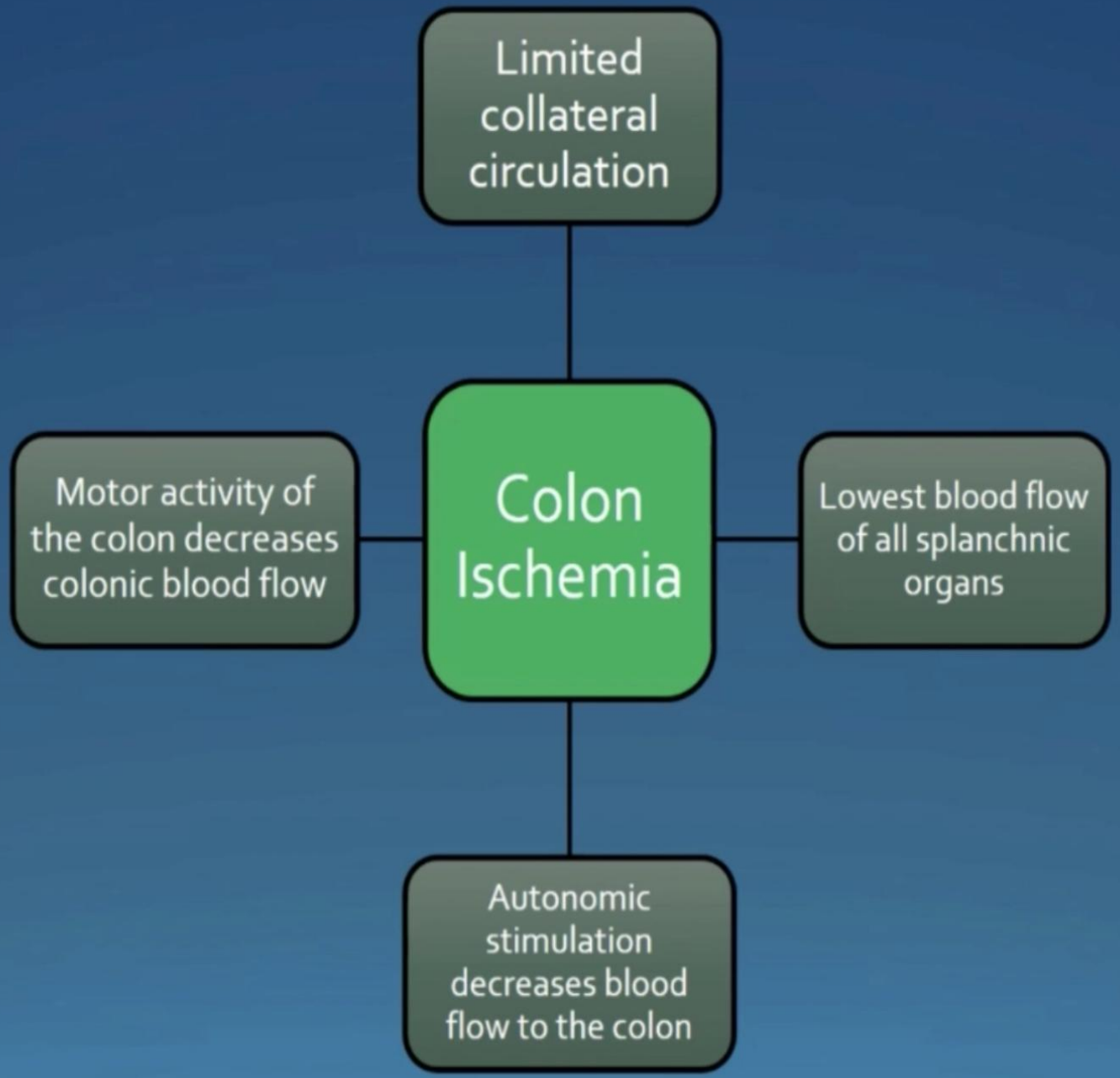
Limited collateral circulation
Motor activity of the colon decreases colonic blood flow
Colon Ischemia
Lowest blood flow of all splanchnic organs
Autonomic stimulation decreases blood flow to the colon

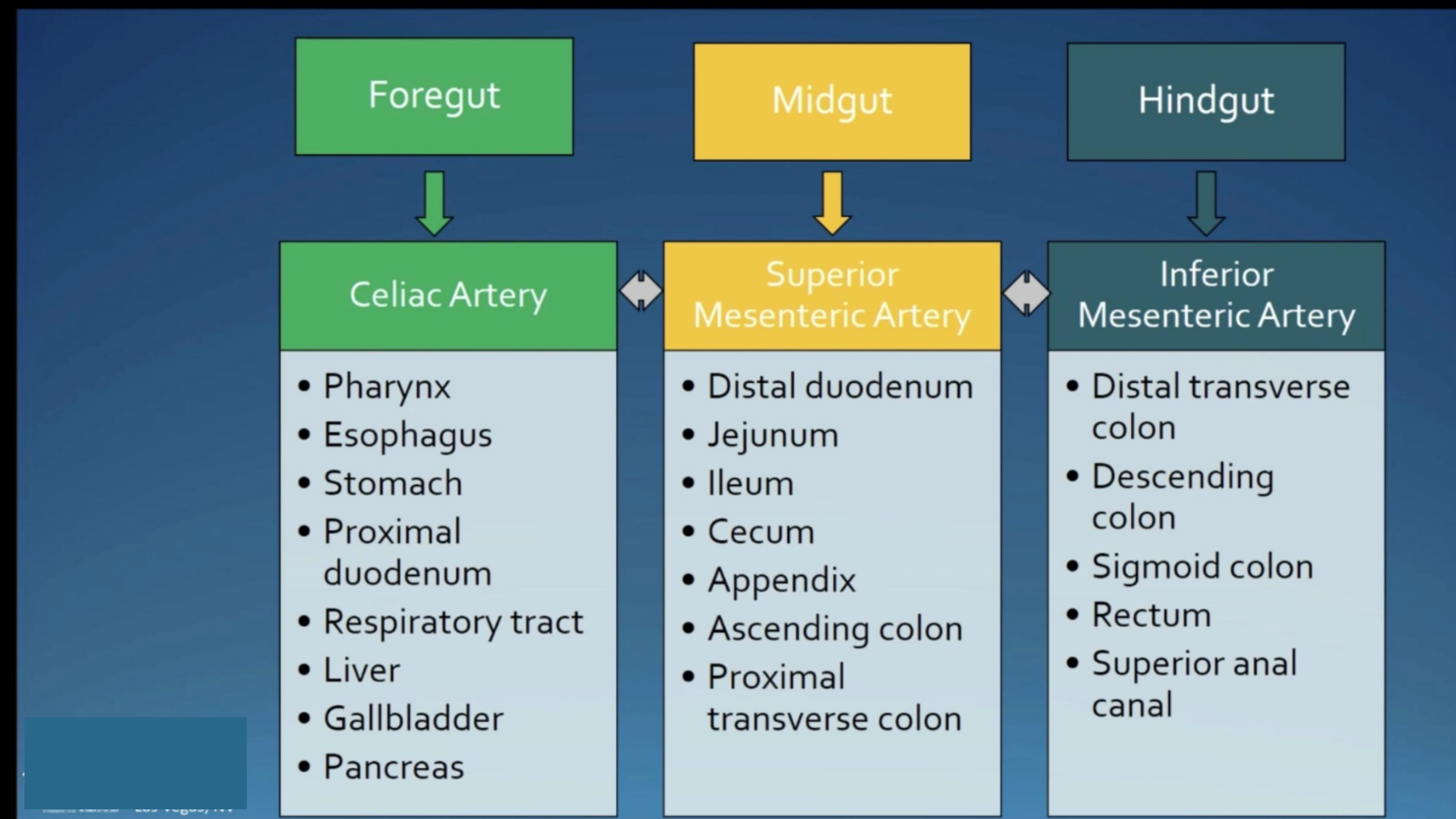
Foregut
Midgut
Hindgut
Celiac Artery
Superior Mesenteric Artery
Inferior Mesenteric Artery
• Pharynx
• Esophagus
• Stomach
• Proximal duodenum
• Respiratory tract
• Liver
• Gallbladder
• Pancreas
• Distal duodenum
• Jejunum
• Ileum
• Cecum
• Appendix
• Ascending colon
• Proximal transverse colon
• Distal transverse colon
• Descending colon
• Sigmoid colon
• Rectum
• Superior anal canal

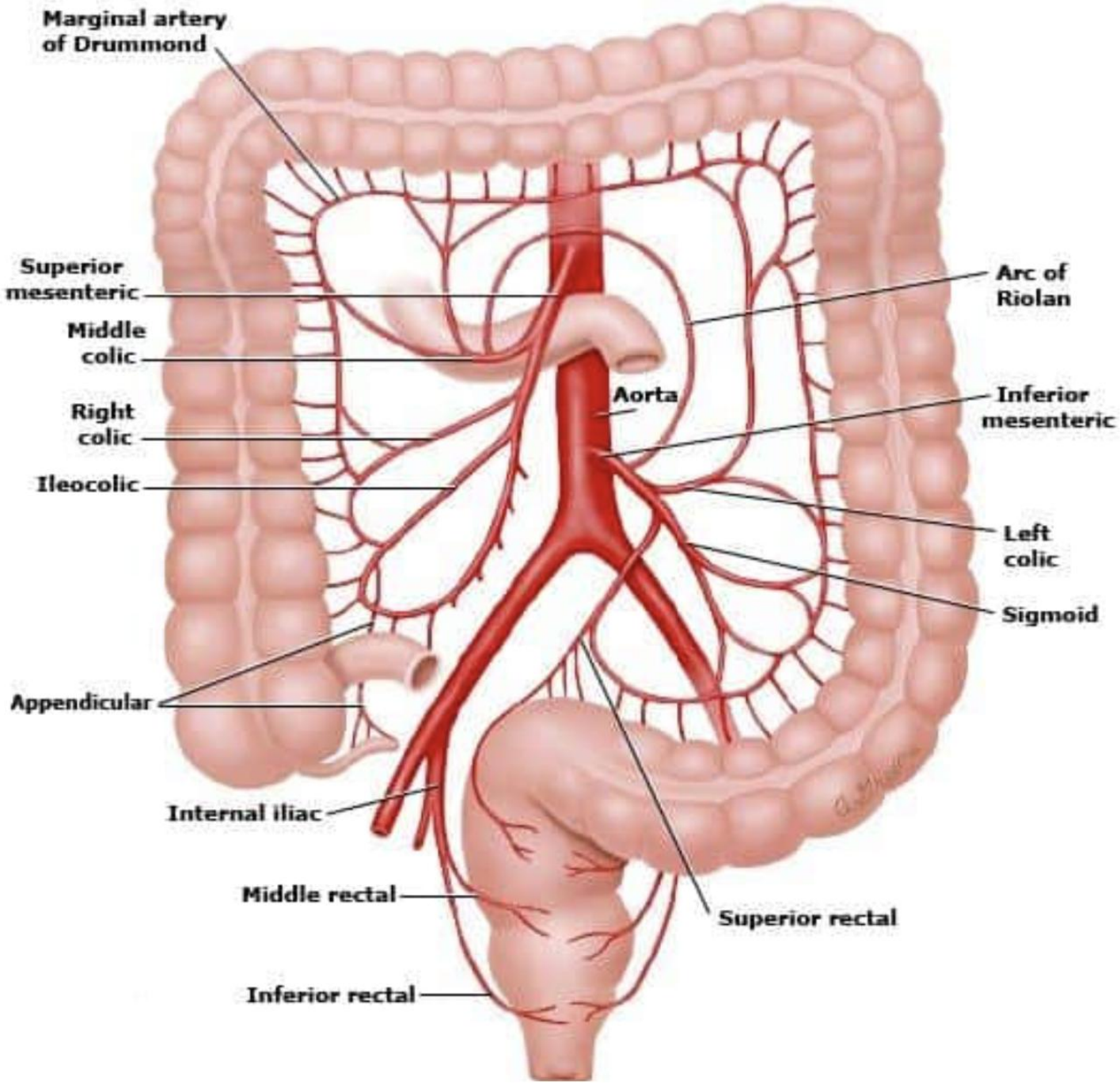
Marginal artery of Drummond
Superior mesenteric
Middle colic
Right colic
Ileocolic
Appendicular
Internal iliac
Middle rectal
Inferior rectal
Arc of Riolan
Aorta
Inferior mesenteric
Left colic
Sigmoid
Superior rectal

Spectrum of Ischemic Disease

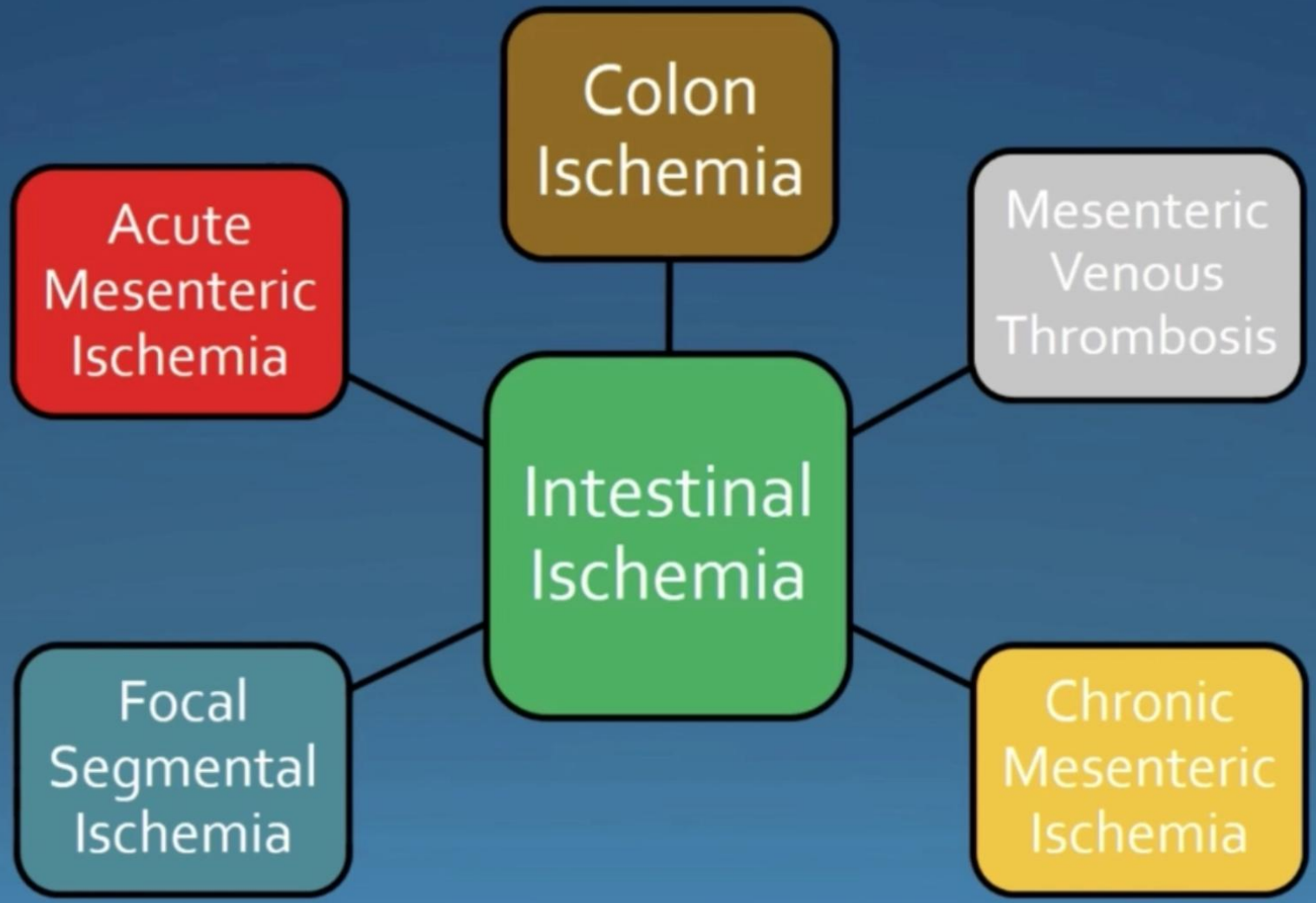

Colon Ischemia

Epidemiology/Risk Factors

Risk factors

- **Drug effects** .
- **Myocardial infarction**
- **Hemodialysis**
- **Aortoiliac instrumentation/surgery Cardiopulmonary bypass**
- **Extreme exercise**
- **Mesenteric arteriovenous fistula or malformation**
- **Acquired or hereditary thrombophilia**
- **Following colonoscopy**

.

Medications Associated with Colonic Ischemia

Strong Association

Class	*Example*	*Class*	*Example*
Constipation-Inducing Medications	**Anti-psychotics** (e.g., quetiapine, clozapine) **Opioid Agonists** (e.g., loperamide, oxycodone, hydrocodone, morphine, codeine) **Muscarinic agonists** (e.g., diphenhydramine, dicyclomine)	Immunomodulators	Lenalidomide Corticosteroids TNF-α Inhibitors
Digoxin		Laxatives	Bisacodyl Glycerin enema Magnesium citrate Polyethylene glycol
Hormonal Therapies	Oral Contraceptive Pills Vaginal Rings	Non-steroidal anti-inflammatory drugs	Aspirin NSAIDS
Illicit Drugs	Amphetamines Cocaine		

Vodusek et al. *Alim Pharm Ther* 2019

Risk factors

- Drug effects .
- Myocardial infarction
- Hemodialysis
- Aortoiliac instrumentation/surgery Cardiopulmonary bypass
- Extreme exercise
- Mesenteric arteriovenous fistula or malformation
- Acquired or hereditary thrombophilia
- Following colonoscopy

.

Risk Factors: Surgical Interventions

- **Abdominal surgery ***
- **Aortic surgery ***
- Cardiovascular surgery
- **Ileostomy***
- Laparoscopy
- Prior colon carcinoma resection

*** Indicates odds ratio of CI being greater than 3**

Chang et al. Neurogast. 2008
Twohig et al. Ind J Gastro. 2020
Walker et al. Am J Gastr. 2004
Yadav et al. Clin Gastr Hep. 2014

Risk factors

- Drug effects .
- Myocardial infarction
- Hemodialysis
- Aortoiliac instrumentation/surgery Cardiopulmonary bypass
- Extreme exercise
- Mesenteric arteriovenous fistula or malformation
- Acquired or hereditary thrombophilia
- Following colonoscopy

.

Nonpharmacologic etiology of colonic ischemia

Mesenteric venous thrombosis

- Hypercoagulable state
- Lymphocytic phlebitis
- Portal hypertension
- Pancreatitis

Small vessel disease

- Diabetes
- Vasculitis
  - Polyarteritis nodosa
  - Lupus erythematosus
  - Takayasu arteritis
  - Granulomatosis with polyangiitis (Wegener's)
  - Anticentromere antibodies
  - Buerger's disease
- Antiphospholipid antibodies
- Amyloidosis
- Rheumatoid arthritis
- Radiation

Shock

- Cardiac failure
- Hemodialysis
- Pancreatitis
- Anaphylaxis

Iatrogenic

Surgical

- Aortoiliac reconstruction
- Cardiopulmonary bypass
- Renal transplant
- Colonoscopy
- Barium enema

Others

- Long-distance running
- Dialysis
- Neurogenic
- Spontaneous in young adults
- Infections (COVID-19, CMV, *Escherichia coli* O157:H7)
- Airplane flight

Major vascular occlusion

- Mesenteric artery thrombosis
- Cholesterol emboli
- Colectomy with IMA ligation
- Aortic dissection
- Aortic reconstruction

Risk Factors for CI: Young versus Old Age



Young (18-64)

- **Medications:**
  - Constipation inducing medications
  - Diuretics
  - NSAIDs
- **Co-morbidities:**
  - COPD
  - Atrial fibrillation



Older (> 65)

- **Medications:**
  - Antipsychotic medications
- **Co-morbidities:**
  - Hypercoagulable state
  - CKD on hemodialysis

Silverman et al. Ali Pharm Ther. 2019; 49:1502-1508

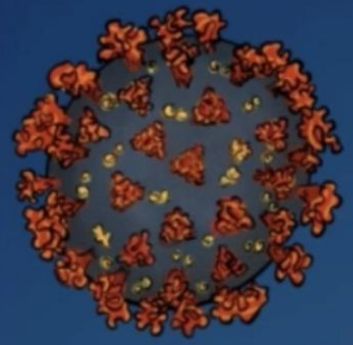

COVID-19 and Colon Ischemia



Epidemiology

Men older than 65 who have developed respiratory failure on mechanical ventilation

Presenting Symptoms

Abdominal pain
Nausea
Diarrhea
Hematochezia

Diagnosis

D-dimer levels ~4 fold increased above normal
Imaging
Colonoscopy (low yield)

Mechanism of Disease

Hypoperfusion secondary to a immunologically mediated cytokine storm rather than a direct interaction of the epithelial cells with virus.

Small vessel thrombosis secondary to hypercoagulability from virus

Cho et al. Case Rep Gas. 2021;15 (1): 408-417
Singh et al. Kor J Gastro. 2020; 76(3): 164-166
Westerhoff et al. Arch Path Lab Med. 2021
Paul et al. Am J Trop Med Hyg. 2021; 104(1): 63-65
Chan et al. Am J Emer Med. 2020; 38(12) 2758. e1-e4

Clinical manifestation

Clinical manifestation

- **Patients with acute colonic ischemia usually present with rapid onset of mild cramping abdominal pain and tenderness over the affected bowel, most often involving the left side .The pain can be associated with an urgent desire to defecate**
- **Compared with ischemia of the small intestine, the cramping pain that accompanies colonic ischemia is usually lateral rather than periumbilically and is often associated with hematochezia.**

Clinical manifestation

- **Mild-to-moderate amounts of rectal bleeding (bright or maroon blood) or bloody diarrhea usually develop within 24 hours of the onset of abdominal pain, though bleeding without prior abdominal pain also occur frequently.**

- **Bleeding may be more common with ischemia of the left compared with the right colon (83.8 versus 36.4 percent in one study .Approximately 15 percent of patients have abdominal pain without evidence of bleeding.**

Colon Ischemia

Diagnosis

Serologic Assessment for ischemic colitis

There are no specific laboratory markers for ischemia, although :

- **increased serum lactate**
- **lactate dehydrogenase (LDH)**
- **creatine phosphokinase (CPK)**
- **amylase**

Imaging



Abdominal X-Ray

"Pneumatosis Linearis"

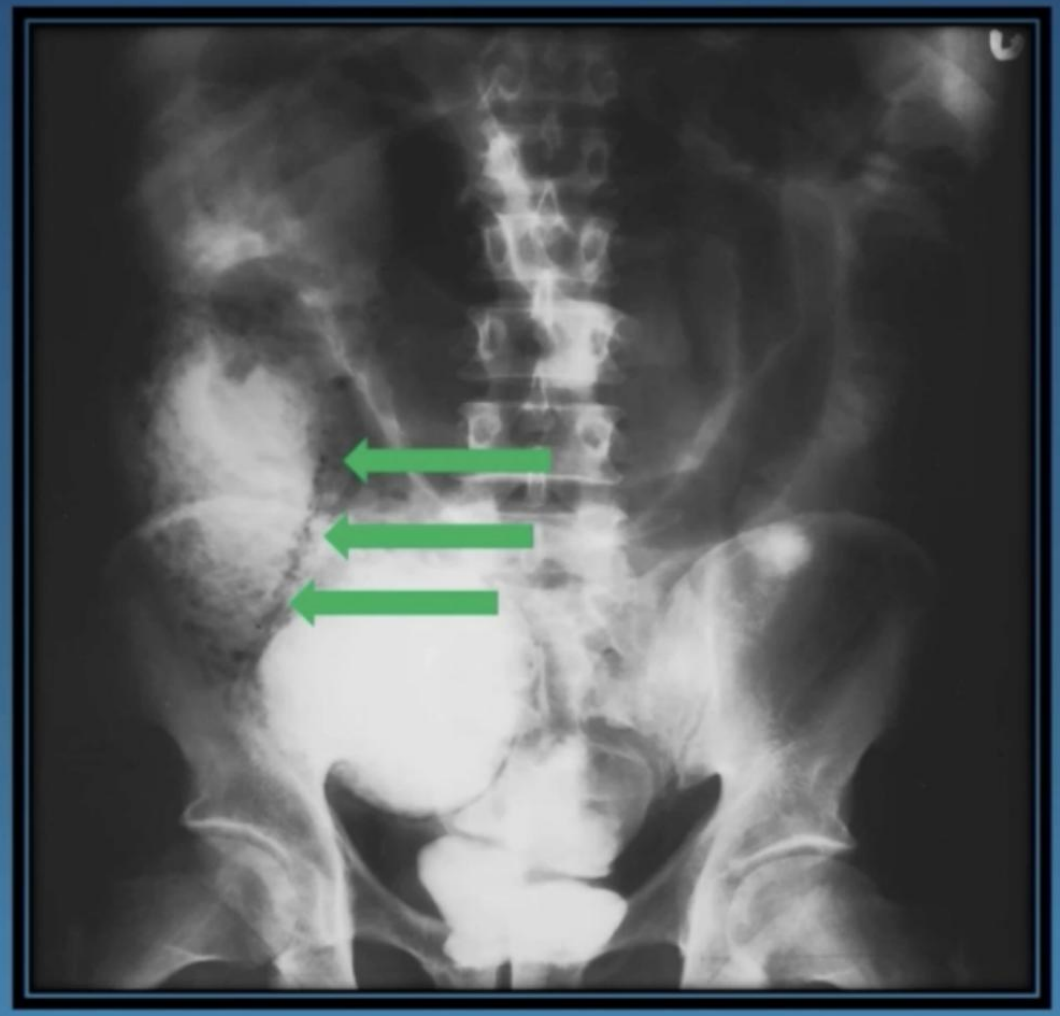



Abdominal X-Ray

"Portal Venous Gas"



CT-Scan




Descendin
DFOV:4

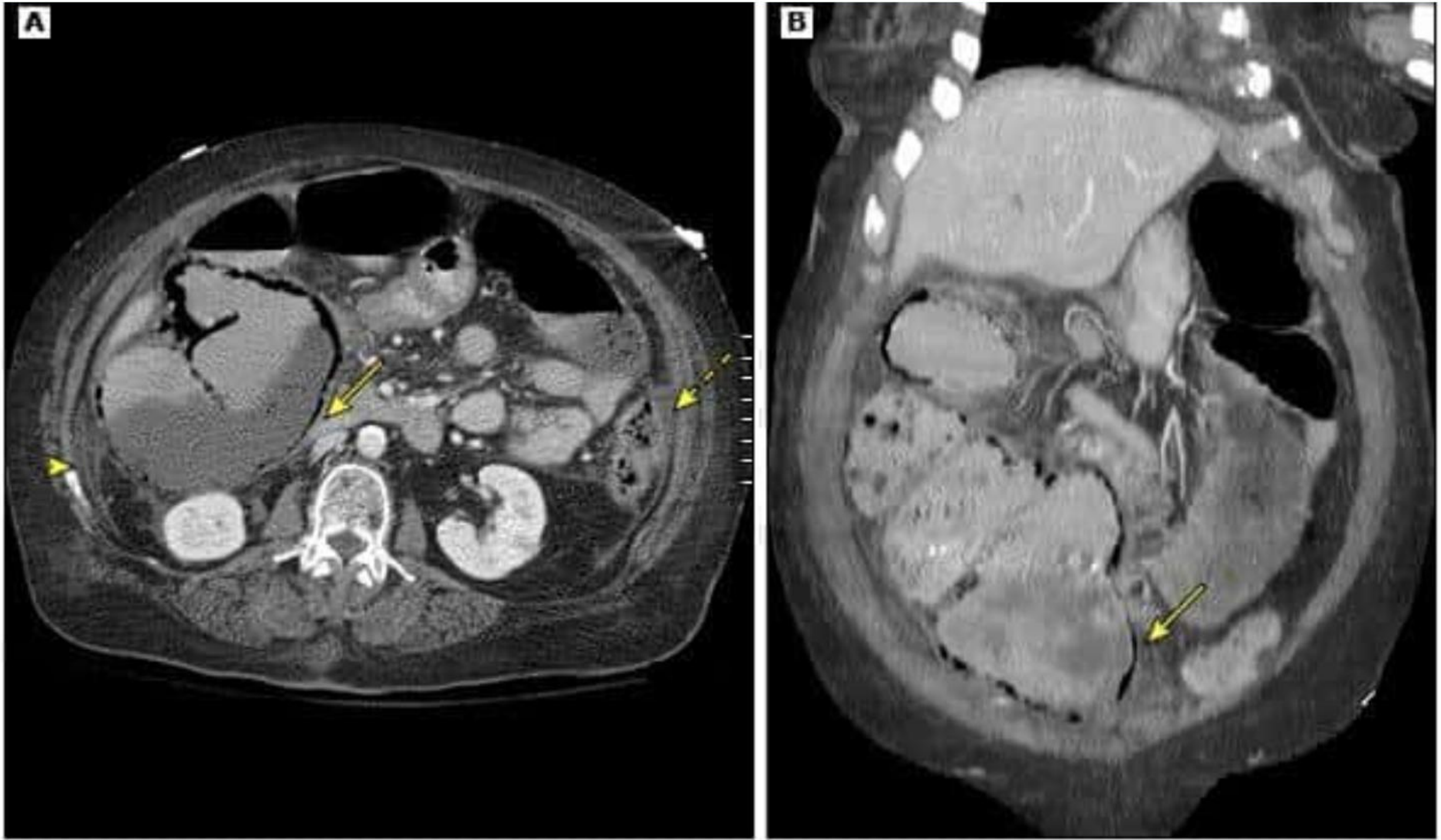
A
B

Colonoscopy

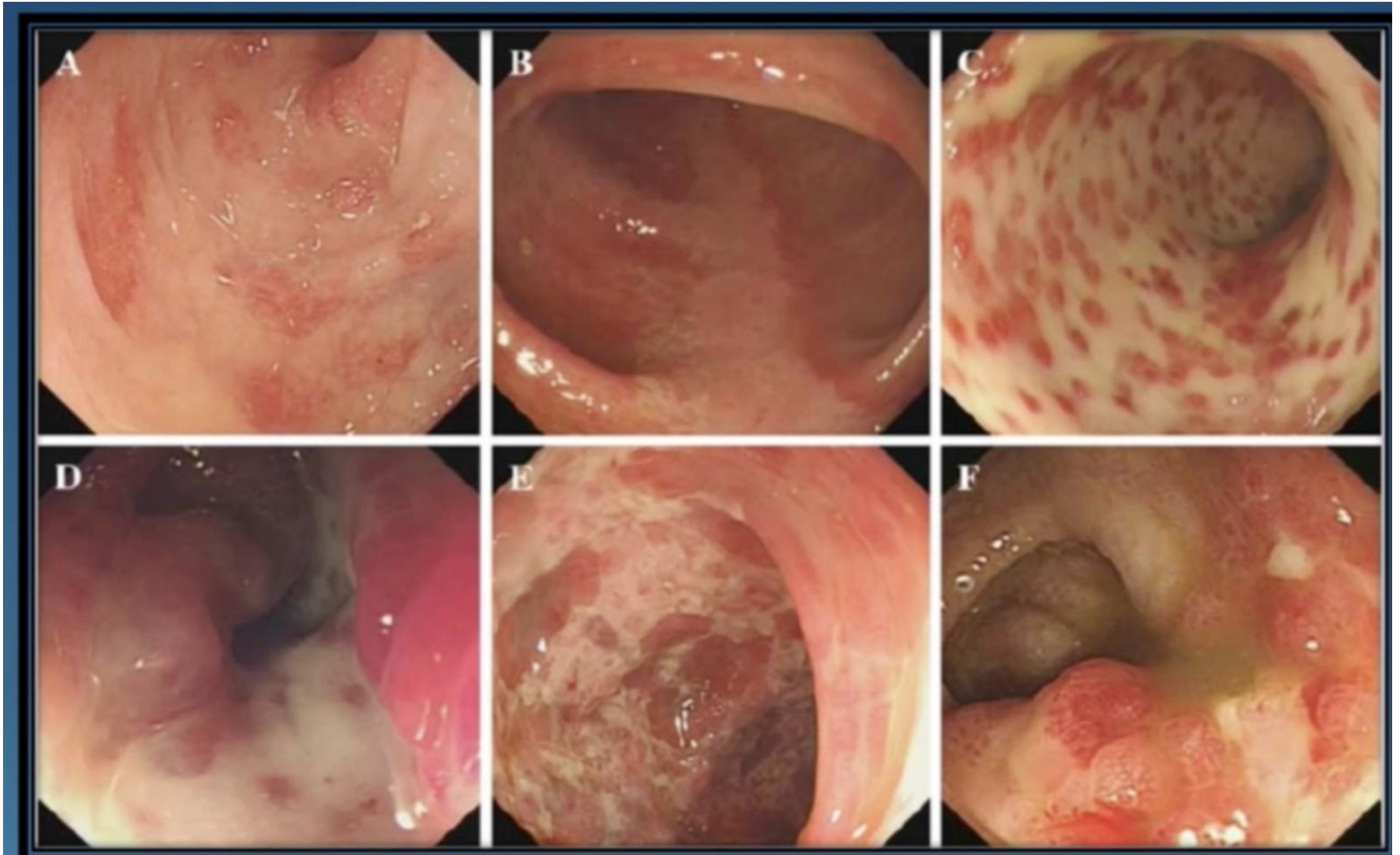
A
B
C
D
E
F

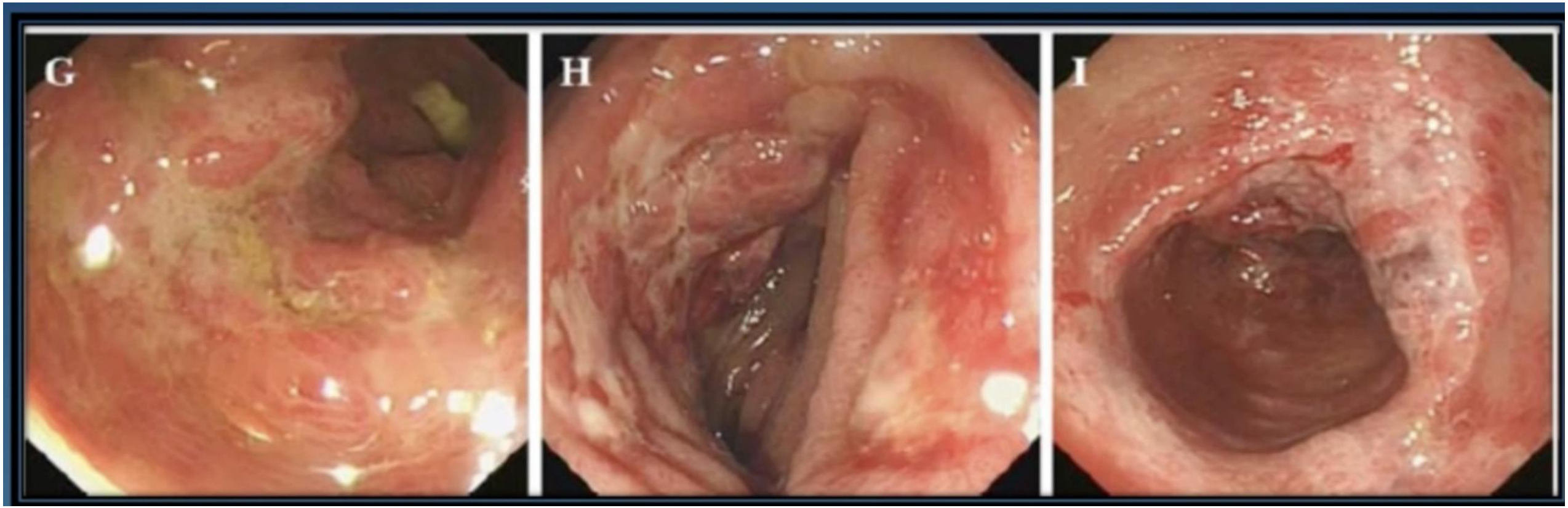
G
H
I

Single Stripe Sign



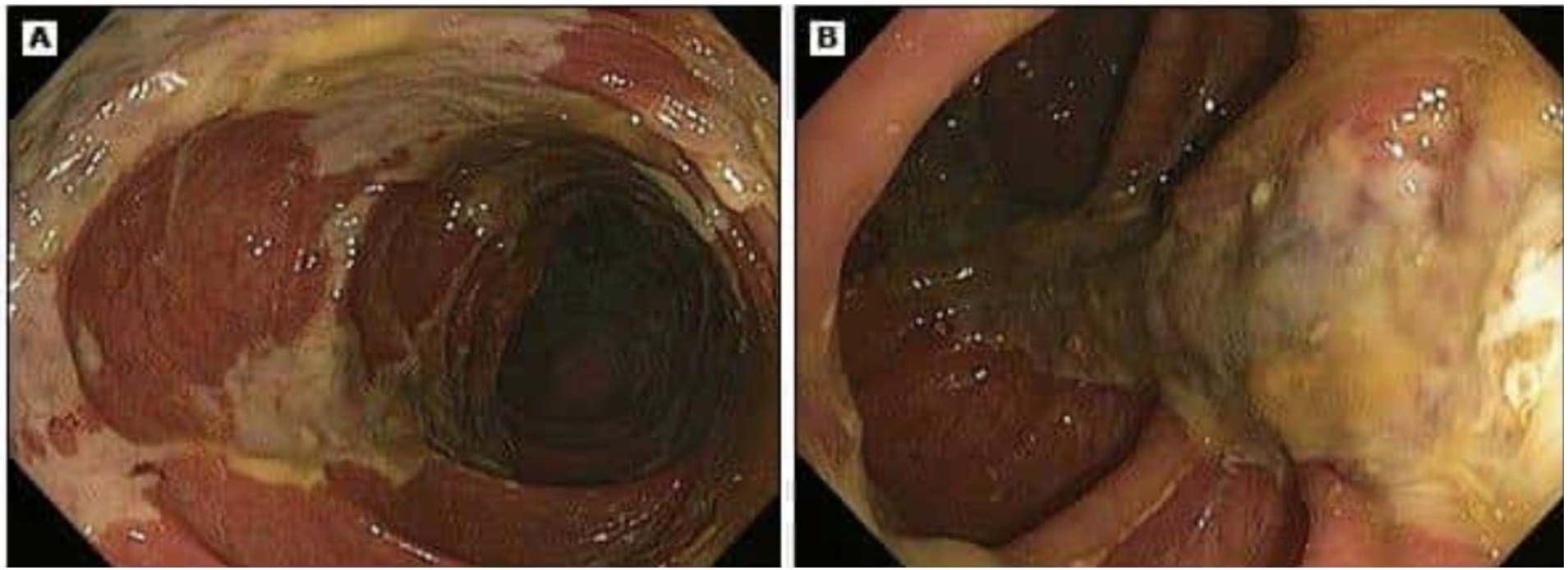
A
B

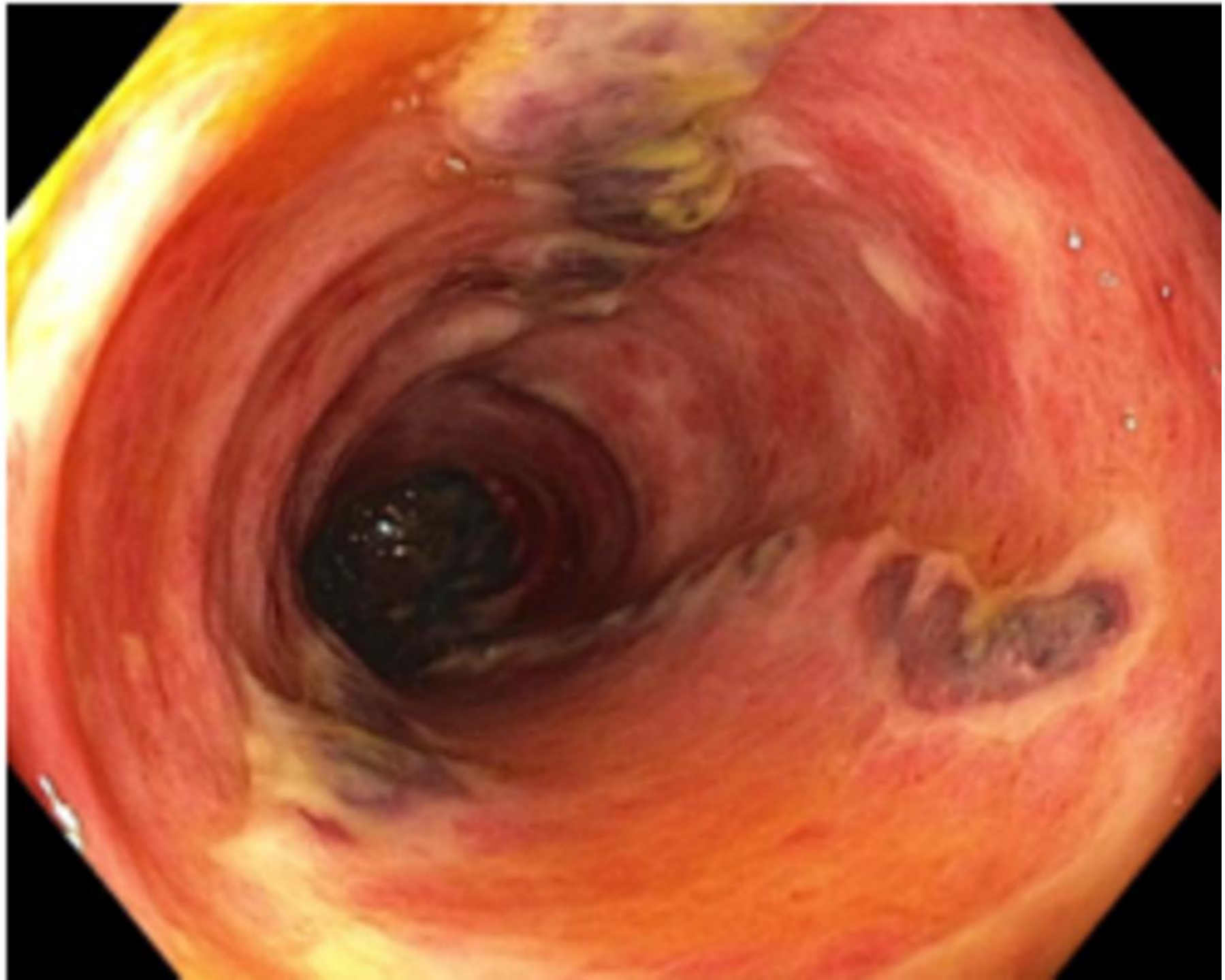

Favier Endoscopic Classification of Ischemic Colitis

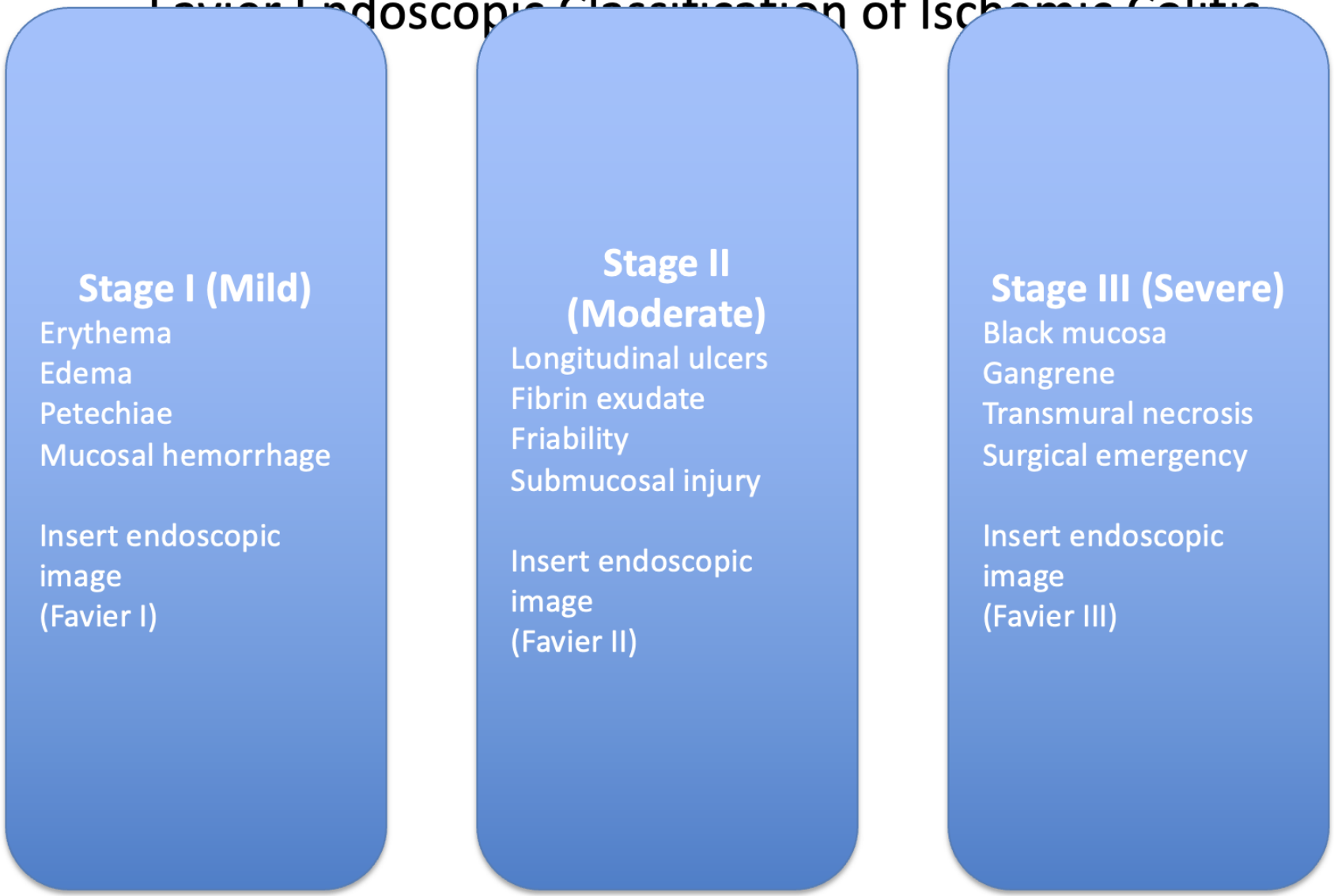

Reference: Favier et al. Endoscopy (1976); Montoro MA et al. World J Gastroenterol. 2021 (PMCID: PMC8589548)

Timing of Colonoscopy



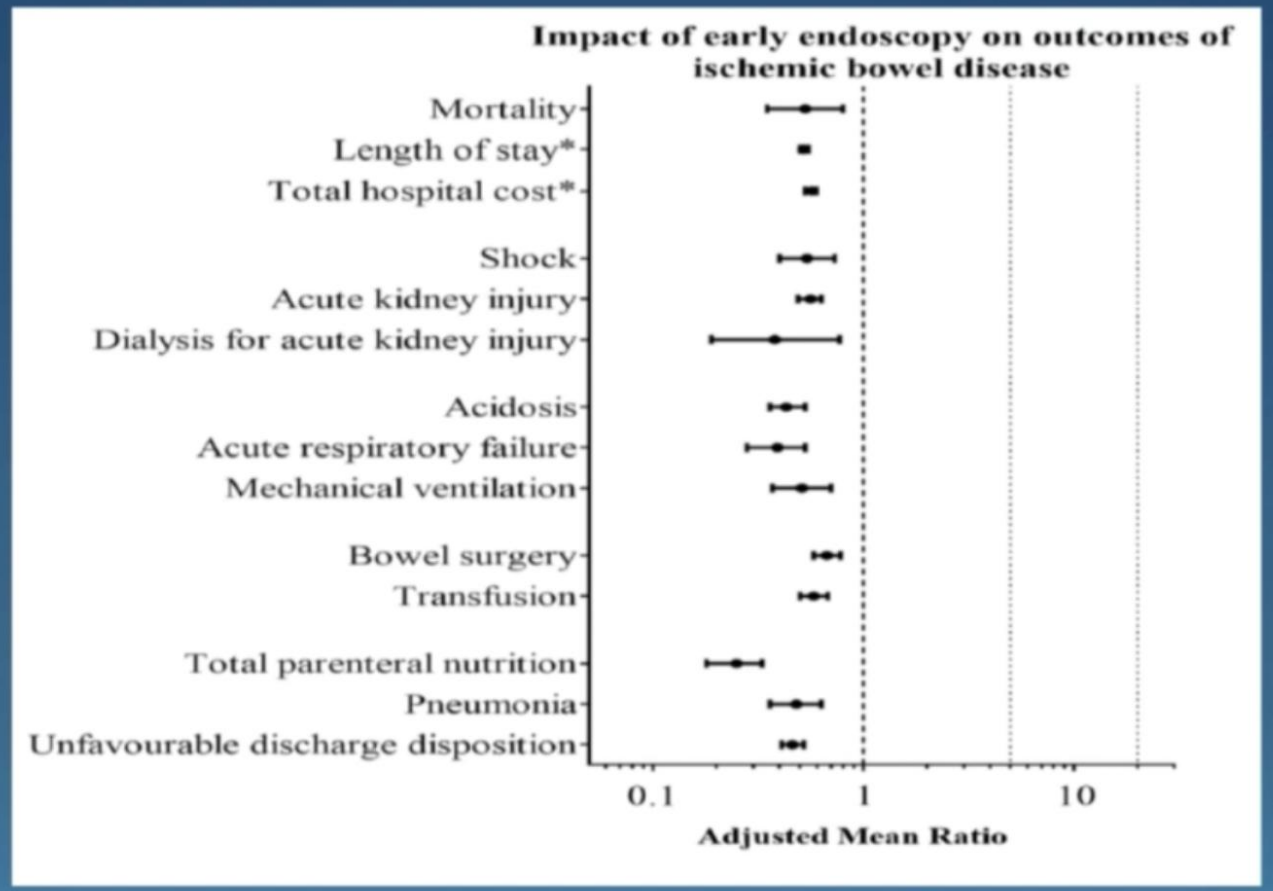



Akanbi and Adajumo Dig Dis Sci (2019) 64:2467-2477

Colon Ischemia

Factors Associated with Poor-Outcome

Mild

Typical symptoms of CI with a segmental colitis not isolated to the right colon and with none of the commonly associated risk factors for poorer-outcome that are seen in moderate disease

Moderate

Any patient with CI and up to three of the following factors:

- *Male gender*
- *Abdominal pain without rectal bleeding*
- *Hypotension (systolic BP < 90 mm Hg)*
- *Tachycardia (heart rate > 100 beats/minute)*
- *White blood cell count > 15 x 10^3/L*
- *Hemoglobin < 12 g/dL*
- *Blood urea nitrogen > 20 mg/dL*
- *Serum sodium < 136 mEq/L*
- *Lactate dehydrogenase > 350 U/L*
- *Colonic mucosal ulceration identified colonoscopically*

Severe

Any patient with CI and more than three of the criteria for moderate disease or any of the following:

- *Peritoneal signs on physical examination*
- *Pneumatosis or portal venous gas on radiologic imaging*
- *Gangrene on colonoscopic examination*
- *Pan-colonic distribution or IRCI on imaging or colonoscopy*

Prediction of Poor Outcome

Recent Models:

Shin et al.

- Tachycardia
- Elevated C-reactive protein
- Favier endoscopic classification ≥ 2
- History of Hypertension

Li et al.

- Neutrophil count
- D-dimer level
- Ischemia of the distal ileum
- Ischemia of the hepatic flexure
- Ulceration
- Luminal stenosis

Li et al. Clin Trans Gastroenterol. 2021 (12) 1-9
Shin et al. Dig Dis Sci. 2020 Nov 26 epub

Poor prognosis

In another review, the presence of four or more risk factors:

- **older than 60**
- **hemodialysis**
- **hypertension**
- **hypoalbuminemia**
- **diabetes mellitus**
- **constipation-inducing medications)**

was 100 percent predictive of colonic ischemia

Differential Diagnosis

- infectious colitis
- inflammatory bowel disease
- diverticulitis
- radiation enteritis
- solitary rectal ulcer syndrome
- colon carcinoma

Colonic ischemia mimic IBD

Patients with IBD commonly present with abdominal pain,diarrhea,hematochezia,and inflammation or ulceration identified On endoscopy.

However these finding are not specific to IBD and lead to broad differential diagnosis.

The differential diagnosis of colonic ischemia also includes

- **infectious colitis**
- **inflammatory bowel disease**
- **diverticulitis**
- **radiation enteritis**
- **solitary rectal ulcer syndrome**
- **and colon carcinoma**

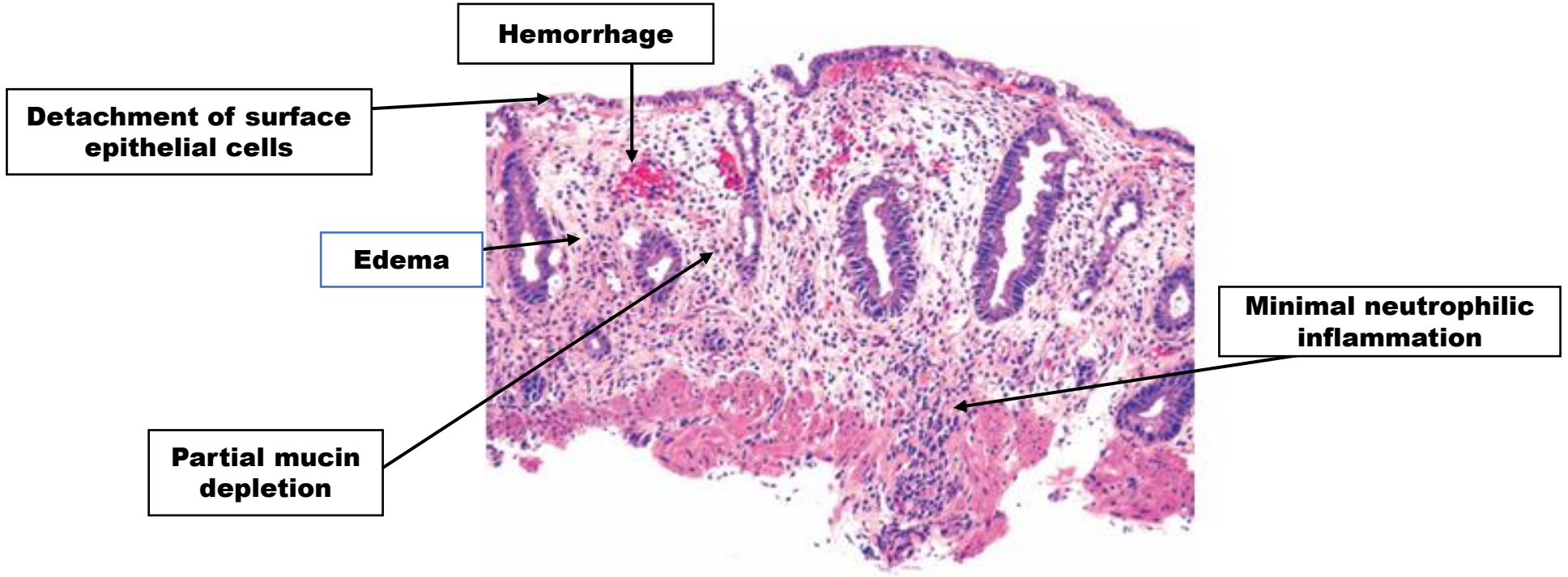
Hemorrhage
Detachment of surface epithelial cells
Edema
Partial mucin depletion
Minimal neutrophilic inflammation

Superficial mucosal erosion

Hyalinized appearance

Withered atrophic crypts

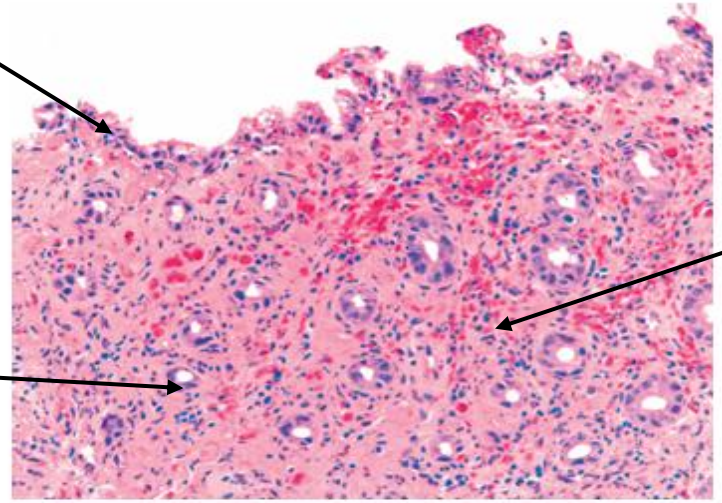

Capillary microthrombi

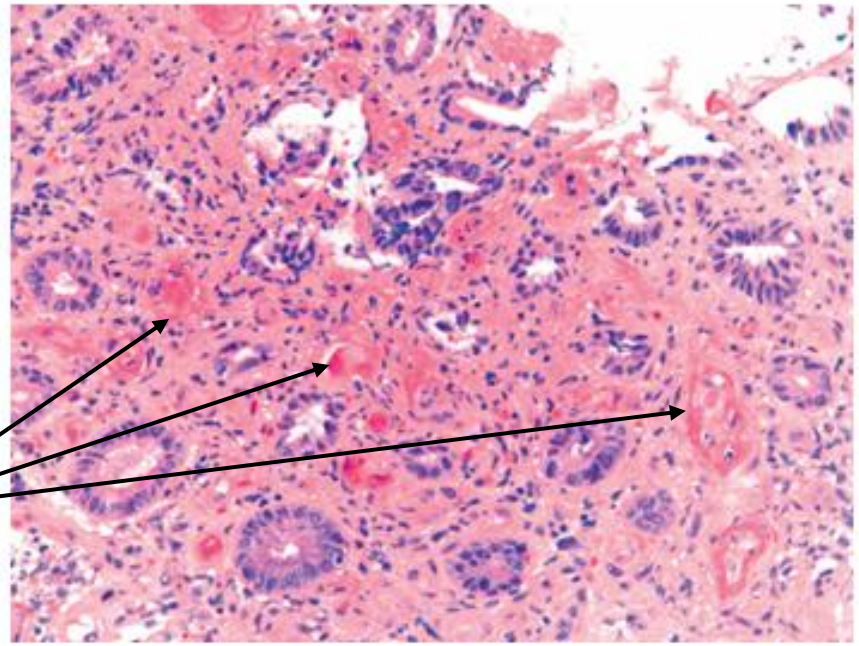


Colon Ischemia
Treatment

Overall Treatment of CI

- Correction of precipitating condition
- NPO
- Intravenous fluids
- Correction of cardiovascular abnormalities
- Optimize forward cardiac flow
- Electrolyte repletion

Probably the most important therapy



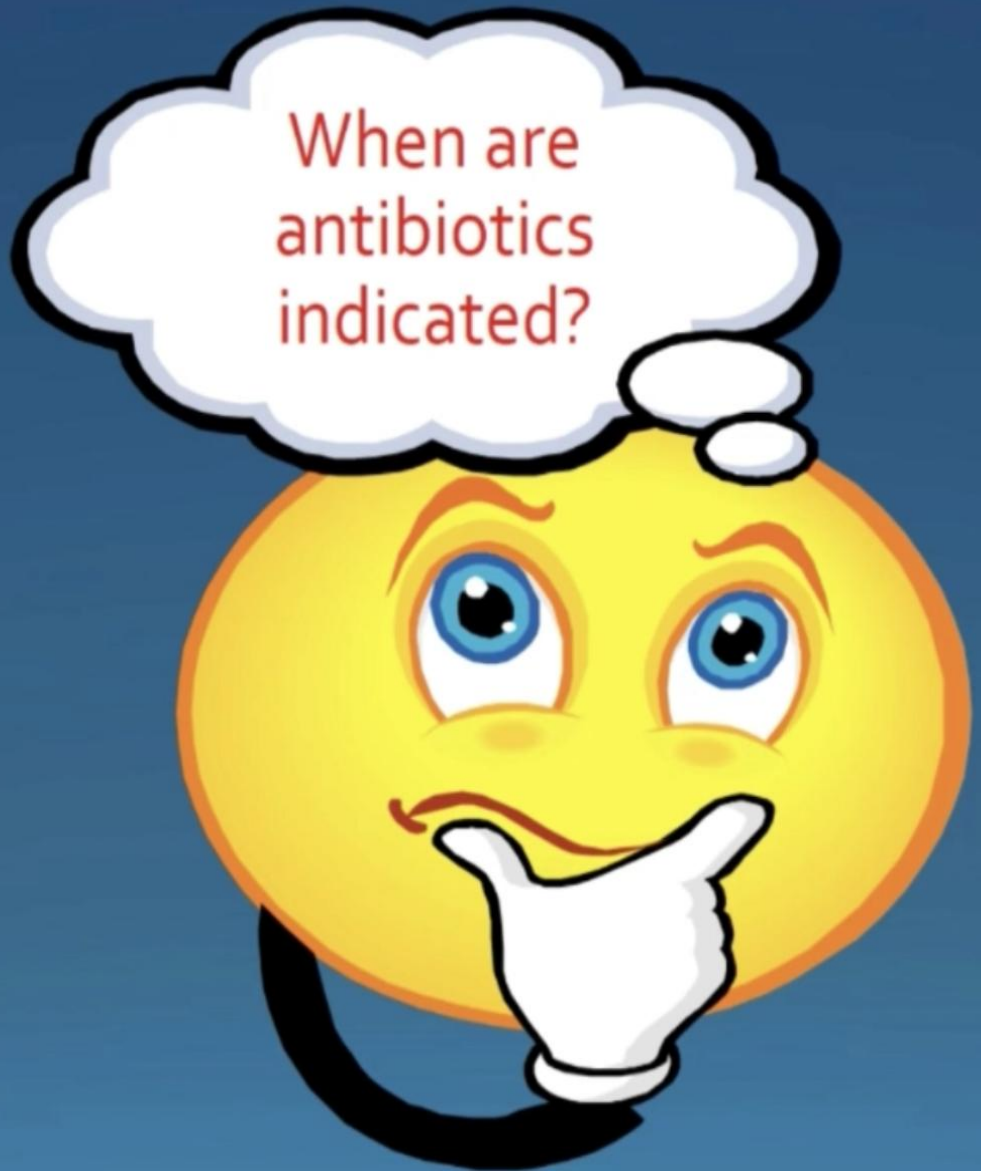
When are antibiotics indicated?

Antimicrobial Therapy

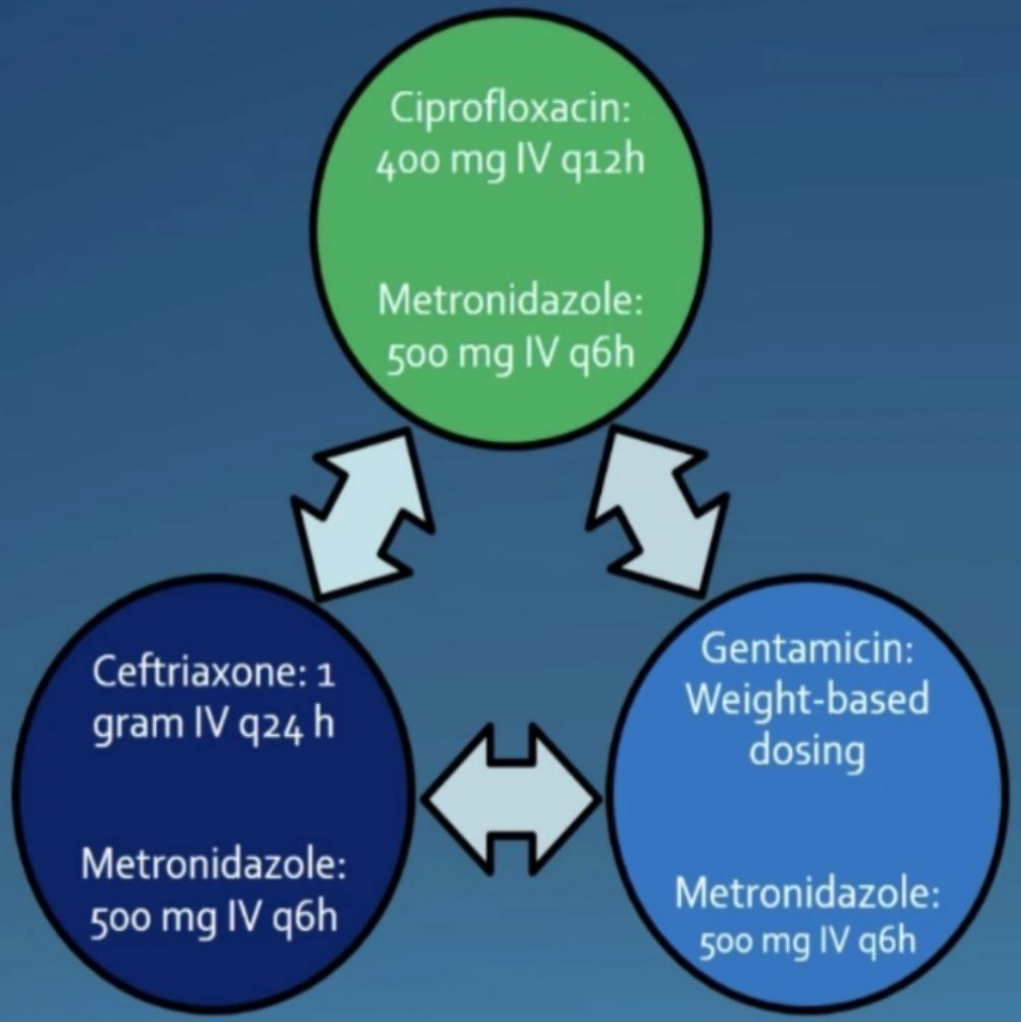

Treatment should include an anti-anaerobic agent plus a fluoroquinolone, aminoglycoside or third-generation cephalosporin

*** Clindamycin is an acceptable substitute for metronidazole**

Case Presentation



58 year old woman

Past Medical History

- Hypertension
- Diabetes

Past Surgical History

- Cholecystectomy

Clinical Presentation

- LLQ pains for 1-2 day's followed by bloody diarrhea

CT Scan

- Segmental colitis in the sigmoid colon

Mild Disease

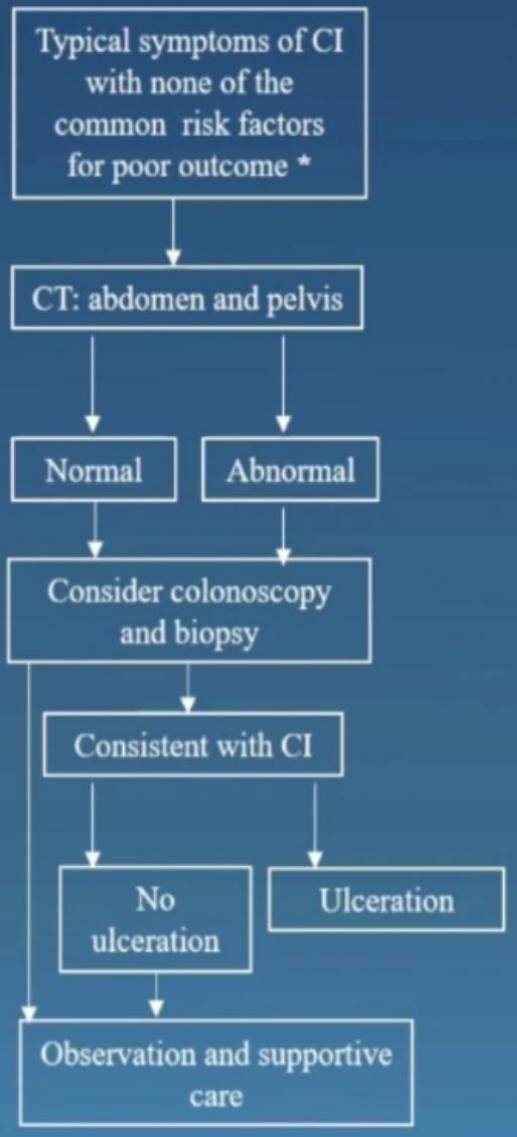

Moderate Disease

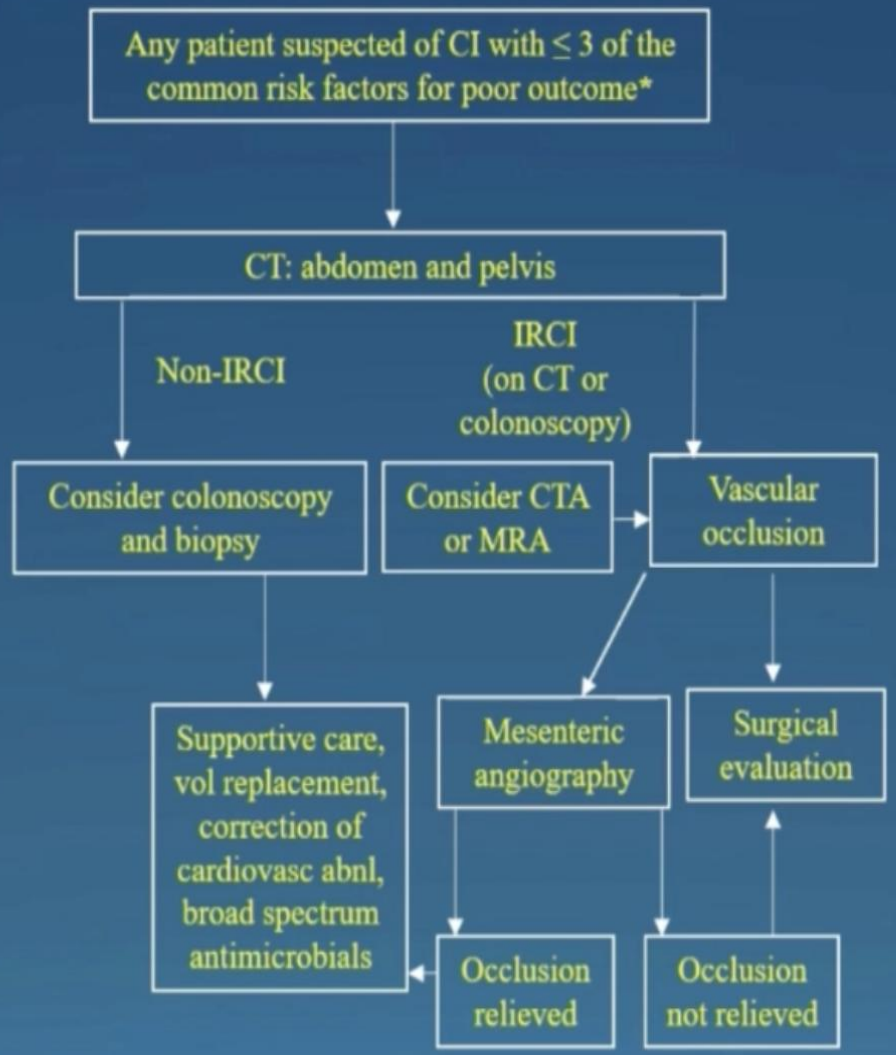

Case Presentation



54 year old man

Past Medical History

- CAD
- COPD

Past Surgical History

- CABG

Clinical Presentation

- RLQ pains for 1-2 day's with non-bloody diarrhea

Serology:

- WBC: 15,600 cells/mm^3
- Hgb: 10.8 g/dL
- LDH: 365 IU/L

CT Scan

- Segmental colitis of the ascending colon

Severe Disease

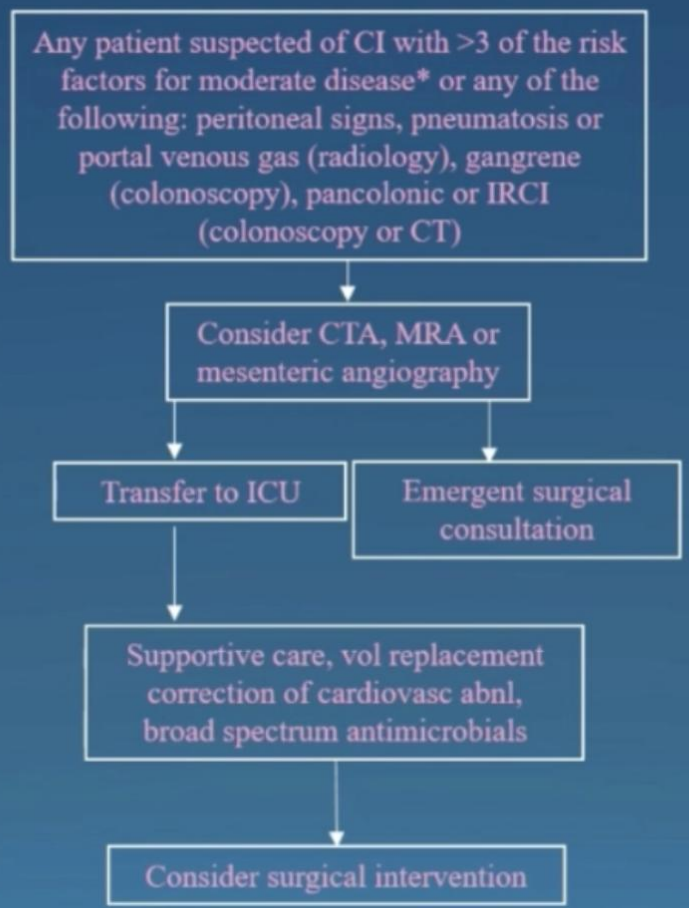

Ischemic Bowel Disease

Acute Mesenteric Ischemia

AMI: Clinical Presentation

Abdominal pain

- Pain out of proportion to exam
- Rebound tenderness
- Muscle guarding

Unexplained abdominal distension

Gastrointestinal bleeding

Colon Ischemia vs. Acute Mesenteric Ischemia

Factor	Colon Ischemia	Isolated-Right Colon Ischemia	Acute Mesenteric Ischemia
Level of illness	Mild		Severe
Most common presenting symptoms	Bright red blood per rectum or bloody diarrhea		Abdominal pains
Best diagnostic study	Colonoscopy		Multi-slice CT scan, Magnetic resonance angiography, Angiography
Identification of precipitating cause	Unusually identified		Commonly identified
Intestinal blood flow at presentation	Normal		Reduced
Prognosis	Excellent		Poor


Thank you!!